





OPEN ACCESS

# Lidocaine infusion for malignant visceral pain: case report

Diana Catalina Velilla Echeverri <sup>1</sup>, Mateo Gómez Díaz,<sup>1</sup>  
Paloma Beltrán Pachón <sup>2</sup>, David Lasso Valenzuela,<sup>3</sup>  
Sofía Poveda Carreño,<sup>3</sup> Marcela Erazo-Muñoz<sup>4</sup>

<sup>1</sup>Pain and Palliative care, Clínica Reina Sofia, Bogotá, Colombia

<sup>2</sup>Pain and Palliative care - Epidemiology, Clínica Reina Sofia, Bogotá, Colombia

<sup>3</sup>Pain and Palliative Care, Fundación Universitaria Sanitas, Bogotá, Colombia

<sup>4</sup>Pain Medicine - Bioethics, Clínica Reina Sofia, Bogotá, Colombia

## Correspondence to

Dr Diana Catalina Velilla Echeverri, Pain and Palliative care, Clínica Reina Sofia, Bogotá 127 #20-78, Colombia; dianacvelilla@gmail.com

Received 27 April 2023

Accepted 25 May 2023

Published Online First

3 July 2023

## ABSTRACT

**Background** Visceral pain accounts for nearly 28% of cancer-related pain, and its effective management poses significant challenges. The diverse pathways of neurotransmission, neurotransmitters, channels, and receptors suggest the need for individualized analgesic therapy. Our objective is to explore a therapeutic alternative for managing malignant visceral pain in advanced cancer.

**Cases** In this report, we present two patients with malignant bowel obstruction and severe visceral pain, despite receiving opioid treatment, necessitating an alternative approach. Surgical interventions were considered but promptly ruled out. Paracentesis was performed as necessary. Pain management was initiated using a combination of opioids and co-analgesics. However, both patients required opioid dose escalation without achieving adequate pain control or tolerating the associated side effects. Consequently, a lidocaine infusion was administered to alleviate pain.

**Outcome** Following 24-48 hours of lidocaine infusion, both patients achieved satisfactory symptom control, enabling a reduction in opioid doses and improvement in intestinal transit. No side effects were reported during the treatment.

**Discussion** Lidocaine infusions may be beneficial for pain management in patients with malignant bowel obstruction and visceral pain. The extent of pain control achieved in comparison to other therapeutics remains challenging to ascertain. We posit that lidocaine infusions, with their potential impact on visceral hypersensitivity, can enhance pain control and facilitate the recovery of bowel transit. Further studies are warranted to validate these findings.

## INTRODUCTION

Visceral pain is responsible for nearly 28% of cancer-related pain. The causes of malignant visceral pain are hepatic, retroperitoneal and peritoneal metastases, biliary obstruction, pancreatic cancer,

visceral organ obstruction and mesenteric infiltration. Patients often describe visceral pain as a vague, dull discomfort pressure-like, intermittently squeezing or cramping, not well-localised and difficult to describe. Distinct neurotransmission pathways, neurotransmitters, channels and receptors suggest that analgesic therapy should be individualised. Proper management of malignant visceral pain is challenging, requiring a multimodal approach that includes medical and interventional/surgical strategies.<sup>1</sup>

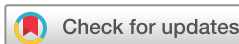We present two case reports of patients with malignant bowel obstruction (MBO) and severe visceral pain who received lidocaine infusion therapy to manage their pain, providing a therapeutic alternative for malignant visceral pain in advanced cancer.

## Case 1

A 44-year-old male patient with metastatic rectal cancer presented to the emergency department with symptoms of nausea, vomiting, abdominal distension, pain and decreased stool through his colostomy. Radiological findings showed ascites and partial bowel obstruction. The patient's Eastern Cooperative Oncology Group (ECOG) performance status was 2, with numeric rating scale for pain 8/10. He was managed conservatively with antiemetics, analgesics and fluid resuscitation. Despite medical management, his symptoms persisted, and he eventually required palliative surgery to relieve the obstruction.

## Case 2

A 66-year-old female patient with peritoneal carcinomatosis and rectovaginal fistula secondary to advanced ovarian cancer presented with symptoms of abdominal distension, vomiting and absence of stool. She had a history of partial intestinal obstruction. Radiological



© Author(s) (or their employer(s)) 2023. Re-use permitted under CC BY-NC. No commercial re-use. See rights and permissions. Published by BMJ.

**To cite:** Velilla Echeverri DC, Gómez Díaz M, Beltrán Pachón P, et al. *BMJ Supportive & Palliative Care* 2023;**13**:e974–e976.

findings showed dilation of intestinal loops with non-incremental air-fluid levels, consistent with a diagnosis of MBO. Her numeric rating scale for pain was 8/10. She was managed conservatively with antiemetics, analgesics and bowel rest. Her symptoms improved with medical management, and she did not require surgery.

After the diagnosis of MBO, the initial medical management included the placement of a nasogastric tube, non-opioid analgesia, antisecretory and antiemetic drugs. Opioid analgesia was given on arrival but stopped shortly after due to dizziness and somnolence. In the case of patient #1, the surgical team was consulted and ruled out palliative surgery. Abdominal paracentesis was performed. For patient #2, the surgical team decided to perform a laparotomy, releasing the adhesions and resecting a retroperitoneal lesion. Medical treatment included ondansetron, haloperidol, scopolamine butylbromide, octreotide and opioids. However, despite optimal treatment, medical and surgical, neither patient #1 nor patient #2 had adequate pain control. In both cases, opioid dose increases were limited due to adverse effects, so it was mandatory to find alternative analgesic approaches.

Twenty-four hours after the lidocaine infusion began, patients experienced greater than a 50% reduction in their baseline pain score without the need for an increase in opioid dose. Patient #1 received 72 hours of lidocaine infusion, while patient #2 received 48 hours. Nausea, vomiting, and output from the nasogastric tube reduced which was subsequently removed. Oral intake improved for both patients, bowels moved and both could be discharged home. No complications during the infusion were reported. We propose that intravenous lidocaine may be beneficial for the management of malignant visceral pain. We believe the low dosage of opioids that our patients required was due to the lidocaine infusion and its effect on visceral hypersensitivity, which also helped reduce its side effects and probably aided in the rapid recovery of bowel transit.

## DISCUSSION

### Visceral pain mechanisms

Malignant visceral pain may occur due to colon afferent sensory nerve endings, responding to physiological stimuli, such as distension, contraction or inflammatory mediators. Pain associated with obstruction activates mechanosensitive nociceptors in visceral afferents, which release of inflammatory mediators, including nerve growth factor (NGF), brain-derived neurotrophic factor and prostaglandins. Voltage-gated sodium channels (VGSCs), especially Nav1.7, Nav1.8 and Nav1.9, play a significant role in visceral pain perception. During obstruction, there is an increase of TTX-r Na<sup>+</sup> currents and upregulation of mRNA expression of TTX-r Nav1.8, resulting

in stretch-induced NGF, a mechanism of hyperalgesia associated with inflammation of the colon.<sup>2,3</sup>

### Lidocaine mechanisms and pharmacology

Lidocaine inhibits VGSC, specifically Nav1.8, and blocks muscarinic (M1, M3) and N-methyl-D-aspartate receptors. Lidocaine's active metabolite, monoethylglycinexylidide, reduces neuronal firing caused by inflammatory pain induction. Intravenous lidocaine is non-linear, and when applied as a continuous infusion, tissues become more saturated, and the half-life prolongs, resulting in a rise in lidocaine concentrations. Infusions lasting more than 12 hours showed unpredictable pharmacokinetics, so it is recommended to reduce the rate of lidocaine infusions after 24 hours to approximately 50%. Intravenous lidocaine is usually given at a loading dose bolus of 1 mg/kg (no more than 1.5 mg/kg), continuing with an infusion of 0.5–1.5 mg/kg/hour. Contraindications include cardiac disease, electrolyte disorders, seizure disorders, renal or hepatic impairment, pregnancy/breast feeding and neurological disorders. Lipid emulsion 20% should be readily available wherever lidocaine is used, in case of signs or symptoms of toxicity.<sup>4,5</sup>

### Limitations

Limitations of this case report include a small sample size, which hinders the generalisation of its findings. Furthermore, there is insufficient literature on lidocaine's dosing and administration protocols. While previous studies have measured lidocaine levels in patients, this is not routinely performed in our setting due to cost and laboratory constraints.

## CONCLUSIONS

Malignant visceral pain is a common symptom in palliative care, often linked to progressive disease and a poor prognosis. Surgical, interventional and medical options must be considered, including opioids. Lidocaine infusion was an effective and safe intervention in both cases of malignant visceral pain in patients with advanced cancer with malignant intestinal obstruction. Its use allowed the reduction of opioid dose and its side effects, along with hospitalisation time. This is a reproducible measure for future studies to research its impact.

**Contributors** DCVE and MGD contributed to the conception and design of the study. DLV and SPC contributed to the data acquisition and patient follow-up. PBP and ME-M contributed to the writing and critical review of the article.

**Funding** The authors have not declared a specific grant for this research from any funding agency in the public, commercial or not-for-profit sectors.

**Competing interests** None declared.

**Patient consent for publication** Consent obtained directly from patient(s).

**Ethics approval** This study was approved by the Ethics Committee of Clínica Reina Sofía. ID (021-22-RP). Participants

gave informed consent to participate in the study before taking part.

**Provenance and peer review** Not commissioned; internally peer reviewed.

**Open access** This is an open access article distributed in accordance with the Creative Commons Attribution Non Commercial (CC BY-NC 4.0) license, which permits others to distribute, remix, adapt, build upon this work non-commercially, and license their derivative works on different terms, provided the original work is properly cited, appropriate credit is given, any changes made indicated, and the use is non-commercial. See: <http://creativecommons.org/licenses/by-nc/4.0/>.

#### ORCID iDs

Diana Catalina Velilla Echeverri <http://orcid.org/0000-0002-2808-4379>

Paloma Beltrán Pachón <http://orcid.org/0000-0002-0436-1749>

#### REFERENCES

- 1 Davis MP. Drug management of visceral pain: concepts from basic research. *Pain Res Treat* 2012;2012:265605.
- 2 Sharma S, Rajagopal MR, Palat G, *et al*. A phase II pilot study to evaluate use of intravenous lidocaine for opioid-refractory pain in cancer patients. *J Pain Symptom Manage* 2009;37:85–93.
- 3 Qi F-H, Zhou Y-L, Xu G-Y. Targeting voltage-gated sodium channels for treatment for chronic visceral pain. *World J Gastroenterol* 2011;17:2357–64.
- 4 Foo I, Macfarlane AJR, Srivastava D, *et al*. The use of intravenous lidocaine for postoperative pain and recovery: international consensus statement on efficacy and safety. *Anaesthesia* 2021;76:238–50.
- 5 Berk T, Silberstein SD. The use and method of action of intravenous lidocaine and its metabolite in headache disorders. *Headache* 2018;58:783–9.