

Palliative stereotactic radiotherapy for metastases during COVID-19: relief when cure is implausible

The COVID-19 pandemic has reoriented radiation oncology towards shorter fractionation schedules. Palliative radiotherapy schedules were already brief, but now there has been a dramatic shift towards single fractions.^{1,2} The fear of SARS-CoV-2 deterred patients' from seeking oncological care at the onset of the pandemic, which has now unfortunately led to more complications presenting to the clinic.

Patient A: A young lady diagnosed with metastatic non-small-cell carcinoma (ROS-1 mutant) and stable on crizotinib for the preceding 2 years, noticed swelling and redness in her left eye (figure 1A–C). She received symptomatic medications from her

general physician during the period of lockdown. Her symptoms worsened to the extent that she was unable to open her left eye, could not perceive light and had pain unresponsive to medications. Investigations revealed an intraorbital metastasis near the inferior pole of the ora serrata. Ophthalmological opinion favoured enucleation, scheduled after 10 days and she was prescribed opioids for pain. Distressed by the combination of pain and disfigurement, and the prospect of further disfigurement after enucleation, she requested palliation for her symptoms. She received fractionated stereotactic radiotherapy (FSRT) (25 Gy in five fractions on consecutive days) via coplanar volumetric modulated arc therapy (VMAT). After two fractions, her symptoms decreased in intensity and a month later, resolved entirely.

Patient B: Another young lady was diagnosed with metachronous

extensive-stage small-cell lung carcinoma after a primary diagnosis of ovarian cancer (in remission for the preceding 2 years). At the onset of the pandemic, she delayed initiation of treatment for fear of contracting the infection. She was compelled to seek treatment when she noticed a painful, progressively enlarging swelling over her scalp, which on examination appeared to be on the verge of fungation (figure 1D–F). Investigations revealed a large calvarial metastasis with bicortical destruction of the left parietal bone and synchronous asymptomatic brain metastases.

Her poor performance status precluded neurosurgical intervention, and she requested palliation from the pain and disfigurement caused by the calvarial metastasis. She received FFSRT (27 Gy in three fractions on consecutive days) via non-coplanar VMAT. After 2 weeks, she reported near-complete clinical resolution of the lesion.

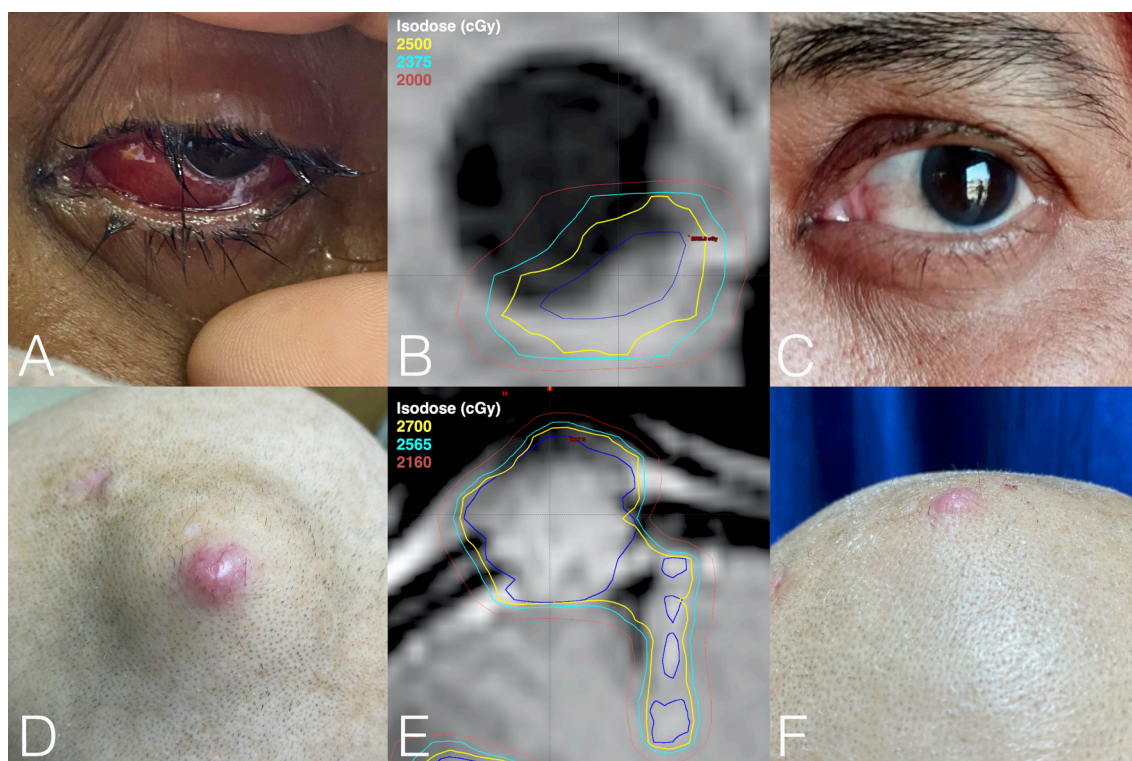


Figure 1 Patient and fractionated stereotactic radiotherapy (FSRT) planning images. (A–C) Pretreatment patient image, FSRT plan superimposed on sagittal MP-RAGE (Magnetization Prepared - RApid Gradient Echo) MRI sequence and Post-treatment (1 month) patient image, respectively. (D–F) Pretreatment patient image, FSRT plan superimposed on sagittal MP-RAGE MRI sequence and Post-treatment (2 weeks) patient image, respectively. In images (B) and (D): gross tumour volume—blue contour; isodoses corresponding to 100%, 95%–80% of prescribed dose—yellow, cyan and pink, respectively.

These cases illustrate the role of radiation oncologists around the world in dealing with the unforeseen consequences of the pandemic on patients with cancer. Though the benefit of FSRT over standard palliative radiotherapy is debated, we offer a higher dose per fraction to control symptoms faster, justifying its value to the patient and also minimising exposure probability to SARS-CoV-2. Moreover, while FSRT in the scenarios above may not improve survival, clearly a role for palliative FSRT exists in the 'art of medicine'.^{3,4} What better way to demonstrate that art than to sculpt radiation isodoses to provide relief?^{4,5}

Kundan Singh Chufal,¹ Irfan Ahmad ,²
Rahul Lal Chowdhary¹

¹Department of Radiation Oncology, Rajiv Gandhi Cancer Institute and Research Centre, New Delhi, India

²Radiation Oncology, Rajiv Gandhi Cancer Institute and Research Centre, New Delhi, India

Correspondence to Dr Irfan Ahmad, Radiation Oncology, Rajiv Gandhi Cancer Institute and Research Centre, New Delhi, India; irfan.a@icloud.com

Twitter Irfan Ahmad @irfanROres

Contributors All authors contributed in patient treatment, article development and editing. KSC was also responsible for article oversight.

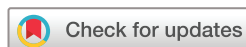Funding The authors have not declared a specific grant for this research from any funding agency in the public, commercial or not-for-profit sectors.

Competing interests None declared.

Patient consent for publication Obtained.

Provenance and peer review Not commissioned; internally peer reviewed.

© Author(s) (or their employer(s)) 2023. No commercial re-use. See rights and permissions. Published by BMJ.



To cite Chufal KS, Ahmad I, Chowdhary RL. *BMJ Supportive & Palliative Care* 2023;**13**:e49–e50.

Received 26 October 2020

Accepted 6 January 2021

Published Online First 19 January 2021

ORCID iD

Irfan Ahmad <http://orcid.org/0000-0003-2944-6797>

REFERENCES

- 1 Passaro A, Addeo A, Von Garnier C, *et al.* ESMO management and treatment adapted recommendations in the COVID-19 era: lung cancer. *ESMO Open* 2020;**5**:e000820.
- 2 Yerramilli D, Xu AJ, Gillespie EF, *et al.* Palliative radiation therapy for oncologic emergencies in the setting of COVID-19: approaches to balancing risks and benefits. *Adv Radiat Oncol* 2020;**5**:589–94.
- 3 Koffer P, Yu E, Balboni TA. Palliative and supportive care. In: Halperin EC, Wazer DE, Perez CA, *et al.*, eds. *Perez & Brady's Principles and practice of radiation oncology*. 7th ed.. Philadelphia: Wolters Kluwer, 2018: 2179–91.
- 4 Sokol DK. "First do no harm" revisited. *BMJ* 2013;**347**:f6426.
- 5 Kantarjian H, Steensma DP. Relevance of the Hippocratic Oath in the 21st Century. *The ASCO Post* 2014;**5**. Available: <http://www.ascopost.com/issues/october-15-2014/relevance-of-the-hippocratic-oath-in-the-21st-century.aspx> [Accessed 10 Oct 2020].