




OPEN ACCESS

# Prospective feasibility study of indigo naturalis ointment for chemotherapy-induced oral mucositis

Kenro Hirata <sup>1</sup>, Yuka Yamada,<sup>2</sup> Yasuo Hamamoto,<sup>1</sup> Kazuyuki Tsunoda,<sup>2</sup> Hiroshi Muramatsu,<sup>3</sup> Sara Horie,<sup>1</sup> Yasutaka Sukawa,<sup>1</sup> Makoto Naganuma,<sup>4</sup> Taneaki Nakagawa,<sup>2</sup> Takanori Kanai<sup>1</sup>

<sup>1</sup>Division of Gastroenterology and Hepatology, Department of Internal Medicine, Keio University School of Medicine, Tokyo, Japan

<sup>2</sup>Department of Dentistry and Oral Surgery, Keio University School of Medicine, Tokyo, Japan

<sup>3</sup>Department of Pharmacy, Keio University Hospital, Tokyo, Japan

<sup>4</sup>The Third Department of Internal Medicine, Division of Gastroenterology and Hepatology, Kansai Medical University, Osaka, Japan

## Correspondence to

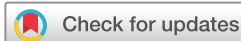Dr Kenro Hirata, Division of Gastroenterology and Hepatology, Department of Internal Medicine, Keio University School of Medicine, Shinjuku-ku, Tokyo, Japan; [kenro916@gmail.com](mailto:kenro916@gmail.com)

Received 21 May 2021

Accepted 28 September 2021

Published Online First

14 October 2021



© Author(s) (or their employer(s)) 2023. Re-use permitted under CC BY-NC. No commercial re-use. See rights and permissions. Published by BMJ.

**To cite:** Hirata K, Yamada Y, Hamamoto Y, et al. *BMJ Supportive & Palliative Care* 2023;**13**:e1001–e1007.

## ABSTRACT

**Objectives** Indigo naturalis, a herbal medicine effective against ulcerative colitis, exhibits anti-inflammatory effects and induces interleukin-22-mediated antimicrobial peptide production. Anti-inflammatory activity and the prevention of secondary infection are essential for the management of chemotherapy-induced oral mucositis (CIOM); therefore, we developed an indigo naturalis ointment to be administered topically for CIOM and evaluated its feasibility.

**Methods** We performed a single-centre, open-label, prospective feasibility study from March 2017 to December 2018. The key eligibility criteria for the subjects were as follows: (1) receiving chemotherapy for a malignant tumour; (2) grade 1 or 2 CIOM and (3) receiving continuous oral care. The treatment protocol comprised topical indigo naturalis ointment application three times a day for 7 days. The primary endpoint assessed was feasibility. The secondary endpoints assessed were the changes in oral findings, oral cavity pain and safety.

**Results** Nineteen patients with CIOM were enrolled. The average feasibility (the proportion of prescribed applications that were carried out) observed in this study was 94.7%±8.9% (95% CI 90.5% to 99.0%), which was higher than the expected feasibility. The revised oral assessment guide scores of the mucous membrane domain and total scores were significantly improved. All patients reported a reduction in oral cavity pain, with a median pain resolution duration of 6 days. No serious adverse events were observed.

**Conclusions** The indigo naturalis ointment was feasible, and showed the potential for efficacy and safety. Larger randomised controlled trials are needed to further assess the efficacy and safety of indigo naturalis compared with a placebo.

**Trial registration number** UMIN000024271.

## INTRODUCTION

Oral mucositis is an adverse event associated with chemotherapy for malignant

## Key messages

### What was already known?

- ⇒ Oral mucositis is a common complication of chemotherapy that is difficult to treat at times.
- ⇒ Indigo naturalis is a herbal medicine that is used in traditional Chinese medicine for various inflammatory diseases.

### What are the new findings?

- ⇒ We developed an ointment of indigo naturalis.
- ⇒ The indigo naturalis ointment was feasible.

### What is their significance?

- ⇒ In the future, larger randomised controlled trials with a placebo control are needed to appropriately evaluate the efficacy and safety of indigo naturalis ointment.

tumours. The subjective symptoms of chemotherapy-induced oral mucositis (CIOM) include pain, discomfort, bleeding, cold and hot sensitivity, redness and swelling in the mouth; desiccation of the oral mucosa; difficulty in opening the mouth/chewing/swallowing; and taste disorders. CIOM significantly lowers the quality of life (QOL) of patients as it makes oral intake difficult.<sup>1</sup> Additionally, CIOM often makes it difficult to complete chemotherapy.<sup>2 3</sup> Generally, 40% of patients treated with anticancer drugs develop CIOM, and approximately half of these patients require a change in the schedule or dosage of anticancer drugs.<sup>4</sup> The antitumour effect of anticancer agents is dependent on drug dose; hence, CIOM management is possibly a key factor in the success or failure of anticancer treatments.

CIOM is considered to develop through (1) the direct inhibition of DNA synthesis by anticancer drugs, (2) oral mucosal

tissue damage from free radicals generated by the inhibition of cellular biochemical and metabolic pathways and (3) tissue damage from inflammatory cytokines released by vascular endothelial cells and macrophages that are activated by free radicals.<sup>5</sup> Moreover, CIOM is exacerbated by secondary infections owing to existing bacterial infections in the oral cavity, undernutrition and suppressed immunity, such as myelosuppression.<sup>5</sup> For these reasons, anti-inflammatory activity and countermeasures against secondary infections are important in the treatment of CIOM; however, there are only a few reports of such treatments.

Indigo naturalis is an herbal medicine extracted from plants such as *Indigofera tinctoria* and *Strobilanthes cusia*. It has been prescribed in China since the 1960s for various inflammatory diseases.<sup>6–8</sup> In a recent randomised, double-blind, multicentre, placebo-controlled trial, we demonstrated the efficacy and safety of administration of oral indigo naturalis powder (0.5–2 g daily) for 8 weeks for the treatment of ulcerative colitis (UC).<sup>9</sup>

One mechanism underlying these therapeutic effects of indigo naturalis is reportedly related to the potent induction of interleukin-22 (IL-22) production.<sup>10</sup> IL-22 promotes antimicrobial peptide production from these epithelial cells, thereby playing an important role in the defence against infection by extracellular pathogens.<sup>11</sup> Moreover, IL-22 may play an important role in organ homeostasis and remodelling, as it promotes the induction of molecules involved in cell differentiation and survival.<sup>12</sup> Additionally, the inhibition of superoxide generation has been reported to be a mechanism underlying the anti-inflammatory effect of indigo naturalis.<sup>13</sup> Therefore, we hypothesised that indigo naturalis administration would be effective against CIOM, and we developed an ointment containing indigo naturalis to be administered topically. In our previous pilot study on the effect of indigo naturalis ointment against oral mucositis induced by inflammatory bowel disease (IBD) including UC in five patients (UMIN000026072), a comparison of the oral findings before and after treatment showed a clear improvement, suggesting that the ointment had a local effect. Therefore, we conducted this study to confirm the treatment potential of topically administered indigo naturalis ointment against CIOM.

## MATERIALS AND METHODS

### Preparation of indigo naturalis ointment

Indigo naturalis is a Chinese herbal medicine, imported in powder form from Fujian, China and purchased from Uchidawakanyaku (Tokyo, Japan). To use indigo naturalis powder in the treatment of CIOM, it was necessary to develop it into a topical form. A previous study reported the use of an ointment made from 20% indigo naturalis powder, 25% Vaseline, 30% yellow wax and 45% olive oil for patients with plaque-type psoriasis.<sup>14</sup> However, when we prepared an ointment

with the same composition, we observed solidification, and the need for heating and dissolving decreased the feasibility of using this formulation as an ointment. Therefore, we used liquid paraffin, which has low antigenicity and is widely used as a base for ointments. Liquid paraffin is refined from mineral oil and is chemically stable because it has no unsaturated groups. Our new indigo naturalis ointment was prepared by adding a small amount of polyethylene resin as a gelling agent. We prepared ointments containing 1%, 5%, 10% and 20% indigo naturalis powder; only mixing was required for preparation of the ointment at all concentrations. The process did not involve heating, and the ointment was easy to apply. For this reason, 20% indigo naturalis ointment with the highest content of active ingredients was chosen as the test drug in this study, and it was prepared at Keio University Hospital by mixing powdered indigo naturalis, liquid paraffin and polyethylene at the ratio of 5:19:1.

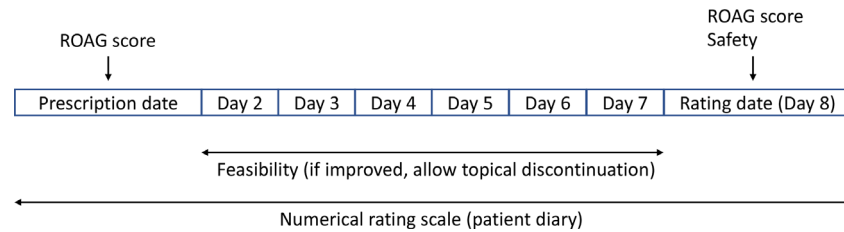
### Study design

This study was a single-centre, open-label, prospective, feasibility study and was conducted in Keio University Hospital. Written informed consent for participation was obtained from all participants in accordance with the principles of the Declaration of Helsinki. Patients signed informed consent regarding publishing their data. This study was prospectively registered in the University Hospital Medical Information Network Clinical Trials Registry (UMIN000024271, 5 December 2016). The first patient was enrolled in March 2017, and the last patient completed the trial in December 2018.

The key inclusion criteria were: (1) receiving chemotherapy for a malignant tumour; (2) grade 1 or 2 CIOM diagnosed by an oral surgeon and (3) receiving continuous oral care from the oral care team in our hospital. The key exclusion criteria were: (1) a history of adverse effects or allergies to Chinese herbal medicine; (2) use of indigo naturalis within a year; (3) serious infection; (4) oral mucositis treatment with other drugs; (5) oral cancer; (6) Sjögren's syndrome and (7) a history of radiotherapy in the head and neck regions.

### Procedures

The study scheme is shown in figure 1. In this study, CIOM was defined as redness, erythema, erosions, aphthae, ulcers, pseudomembranes and haemorrhage of the oral mucosa occurring during anticancer drug treatment. The oral cavity of patients with CIOM was evaluated using the National Cancer Institute Common Terminology Criteria for Adverse Events (NCI-CTCAE) V.4.0 and Revised Oral Assessment Guide (ROAG) scores<sup>15 16</sup> were assigned by an oral surgeon. The pain of CIOM was assessed by the patients themselves using the Numerical Rating Scale (NRS).<sup>17</sup> The patients were prescribed indigo naturalis



**Figure 1** Scheme of the feasibility study of indigo naturalis ointment for chemotherapy-induced oral mucositis. ROAG, revised oral assessment guide.

ointment on day 1, and its topical application was indicated three times a day for 7 days. The patients were provided with a diary to write down how many times a day they were able to apply the ointment and what their daily NRS score for pain was. Treatment discontinuation was allowed if the oral cavity pain was alleviated. The patients returned to the hospital on day 8 for evaluation of their ROAG scores and assessment of adverse effects. A delay of up to 2 days was allowed if the patients were unable to visit the hospital because of a holiday or other reasons. During the study period, no other antioral mucositis drugs including analgesics were allowed.

#### Outcomes

The primary outcome was feasibility, which was defined as the proportion of prescribed applications that were carried out between days 2 and 7, excluding the date of the prescription. If oral cavity pain was reduced and the topical indigo naturalis ointment was discontinued before day 7, feasibility was assessed from day 2 to the time of treatment discontinuation. The secondary outcomes were the degree of improvement in oral findings and function, oral cavity pain and safety. The degree of improvement in oral findings and function was assessed by comparing pretreatment and post-treatment ROAG scores. The NRS score of oral cavity pain was assessed daily from day 1 to the day of re-evaluation according to the patients' diaries. The severity of adverse events was graded according to NCI-CTCAE V.4.0.

#### Sample size calculation and statistical analysis

By referring to the feasibility in the previous pilot study in subjects with IBD-induced oral mucositis, the threshold feasibility for the present study was set to 70%, and the expected feasibility was set to 90%. The required sample size was estimated based on the threshold feasibility of 70%, expected feasibility of 90%, power of 80% and an alpha value of 0.1 (one sided) using the binomial test. Given that 10% of the patients may be ineligible for the study, the target sample size was determined to be at least 19 patients. The enrolment period was set to 2 years, and the follow-up period was set to 2 weeks from the enrolment of the last patient.

As a primary analysis, the feasibility of the topical use of the indigo naturalis ointment was analysed in accordance with intention-to-treat principles. The ROAG scores before and after treatment were compared using a Wilcoxon signed-rank test. The NRS scores on the first day and the scores from days 2 to 8 were compared using Steel's multiple comparison test. Statistical significance was defined as  $p < 0.05$ . The data are expressed as mean  $\pm$  SD. All statistical analyses were performed using SPSS Statistics V.26 (SPSS). All authors had access to the study data and reviewed and approved the final manuscript.

## RESULTS

#### Patient profiles

From March 2017 to December 2018, 19 patients (17 men and two women) with CIOM were enrolled. Patient characteristics are listed in [table 1](#). All patients had developed CIOM although their oral care had been supervised. At the time of enrolment, the median age of the patients was 64 (range: 37–83) years. Fourteen patients (73.7%) had grade 1 and five patients (26.3%) had grade 2 oral mucositis. Multiple oral mucositis was observed in 10 patients (52.6%) and single oral mucositis was observed in nine patients (47.4%). Overall, 12 of the 19 patients (63.2%) had received fluoropyrimidines and seven of the 19 patients (36.8%) had received platinum-based therapy.

#### Feasibility of indigo naturalis ointment

The feasibility of indigo naturalis ointment is shown in [figure 2](#). All patients maintained a threshold level of 70% feasibility. The average feasibility of  $94.7\% \pm 8.9\%$  (95% CI 90.5% to 99.0%) was higher than the expected feasibility ([figure 2A](#)). Thirteen of the 19 patients discontinued treatment during the study because of a reduction in oral mucositis pain ([figure 2B](#)). None of the patients discontinued the treatment owing to application difficulties or other reasons despite residual oral mucositis pain.

#### Changes in oral findings and functions

The total ROAG scores of each of the eight domains are shown in [figure 3](#). The mean total ROAG score before the start of treatment was  $10.7 \pm 1.1$  points. Before treatment, oral functions such as voice and

**Table 1** Characteristics of patients with chemotherapy-induced oral mucositis

	Chemotherapy-induced oral mucositis (n=19)
Median age, years (range)	64 (37–83)
Sex (male/female)	17/2
ECOG PS	
0	8 (42.1%)
1	10 (52.6%)
2	1 (5.3%)
CTCAE grade of the oral mucositis	
1	14 (73.7%)
2	5 (26.3%)
No of lesions	
Single	9 (47.4%)
Multiple	10 (52.6%)
Lesion site of oral mucositis	
Oral membrane	
Buccal mucosa	7 (36.8%)
Palate	4 (21.1%)
Labial mucosa	10 (52.6%)
Floor of mouth	1 (5.3%)
Gum	2 (10.5%)
Tongue	6 (31.6%)
Disease	
Oesophageal cancer	2 (10.5%)
Gastric cancer	4 (21.1%)
Colorectal cancer	8 (42.1%)
Pancreatic cancer	3 (15.8%)
Neuroendocrine tumour	2 (10.5%)
Anticancer agent	
Fluoropyrimidine	12 (63.2%)
Platinum	7 (36.8%)
Taxane	3 (15.8%)
Anti-VEGF	4 (21.1%)
Anti-EGFR	4 (21.1%)
Gemcitabine	2 (10.5%)
Sunitinib	1 (5.3%)
Everolimus	1 (5.3%)
Mitomycin	1 (5.3%)

CTCAE, Common Terminology Criteria for Adverse Events V.4.0; ECOG, Eastern Cooperative Oncology Group; EGFR, epidermal growth factor receptor; PS, performance status; VEGF, vascular endothelial growth factor.

swallowing were not impaired in the patients with CIOM, and they tended to have high scores for oral mucosa or tongue (redness and ulcers) and teeth (presence of plaque and food residue). After 1 week of the topical application of indigo naturalis ointment, the total ROAG score decreased significantly to  $9.4 \pm 1.6$  points ( $p < 0.01$ ). In the analysis of each of the eight domains that make up the ROAG score, the domain score for the mucous membrane was significantly reduced by treatment with indigo naturalis ointment from  $2.6 \pm 0.7$  to  $1.5 \pm 0.6$  points ( $p < 0.01$ ). No

significant changes were observed in other domains. The improvement in the findings of oral mucositis of the gum and tongue before and after treatment in two patients is shown in figure 4. Although the ointment is black in colour, no oral coloration was observed.

### Changes in oral pain

The change in the mean NRS score for oral cavity pain of CIOM patients during the treatment period is shown in table 2. There was a significant decrease in the NRS score after 4 days of treatment compared with that after 1 day of treatment. Some patients showed a temporary increase in oral cavity pain on day 2 or 3 after the start of treatment; however, in all patients, the intensity of pain was lower after the treatment than before the treatment. The median time to complete resolution of pain after the start of treatment was day 6.


### Safety

Although 17 patients had no adverse events owing to the topical application of indigo naturalis ointment, one patient had grade 1 malaise and one had grade 1 rash. The patient who developed malaise was receiving chemotherapy with a fluoropyrimidine and a platinum-based drug for gastric cancer. CIOM appeared on day 6 of the eighth cycle of chemotherapy, topical application of indigo naturalis ointment was started on day 9, and malaise appeared on day 12. The malaise was reported to be transient and decreased within 1 day, and since the patient was able to complete 1 week of topical application, we concluded that it was most likely an adverse event of chemotherapy. The patient who complained of a rash was receiving chemotherapy with fluoropyrimidine for oesophageal cancer. A grade 1 chest rash appeared from days 2 to 5 after the start of topical indigo naturalis ointment. On day 8 of the visit, the rash had disappeared despite the continuation of ointment until day 8; hence, the rash was unlikely to be a treatment-related adverse event. In addition, after up to 1 year of follow-up, there were no late-onset adverse events or secondary cancers that was related to the indigo naturalis ointment application in all patients.

### DISCUSSION

We developed an ointment containing indigo naturalis powder, which is a potential treatment for UC. In addition, we conducted a feasibility study to determine whether the newly developed indigo naturalis ointment could be applied to patients with CIOM. The results confirmed the high feasibility of indigo naturalis ointment. None of the patients discontinued the product due to difficulties in application or the occurrence of adverse events. In addition, the study showed promising efficacy and safety of the ointment. The results of this study are clinically meaningful in the management



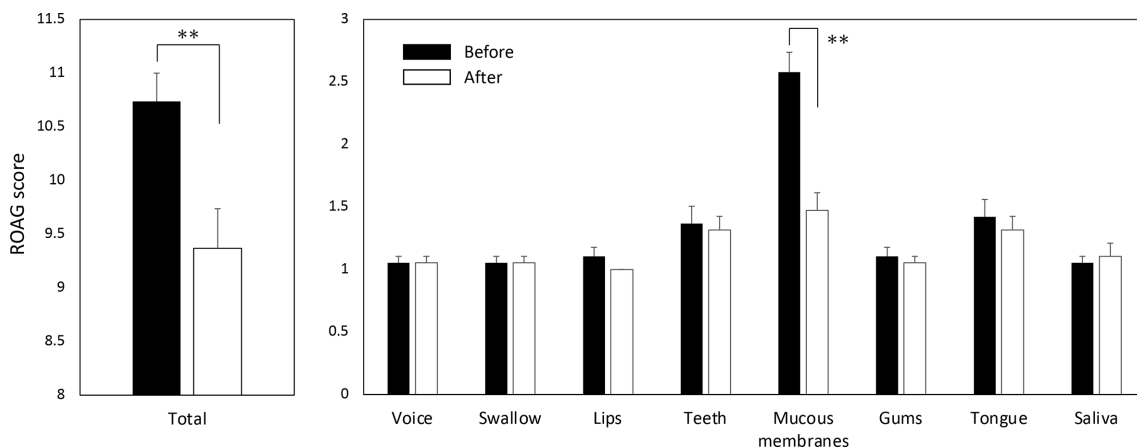


**Figure 2** Feasibility of the topical application of indigo naturalis ointment for all participants with chemotherapy-induced oral mucositis. (A) Feasibility (%) of indigo naturalis in each patient. (B) Details of the feasibility data from days 2 to 7. Orange squares indicate topical application, and black squares indicate no topical application. Black circles indicate self-discontinuation of topical application owing to the alleviation of pain.

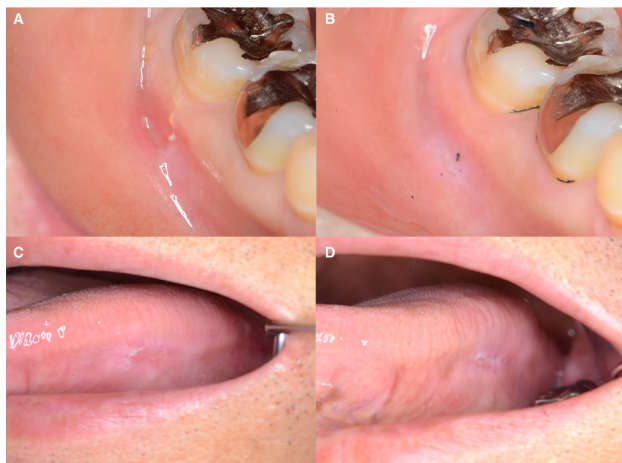of CIOM, for which no standard treatment has been established.

In this study, the ROAG and NRS scores of oral cavity pain were used as oral assessment tools to evaluate the efficacy of indigo naturalis ointment. The ROAG score is a comprehensive oral assessment tool developed for patients undergoing bone grafting or chemotherapy and consists of eight items. It includes assessments of voice, ability to swallow, lips, teeth, mucous membranes, gums, tongue and saliva. Thus, with these scores, not only oral mucositis but also the functional impairment associated with oral mucositis can be determined simultaneously and analysed in greater detail than with the WHO grading scale for oral mucositis.<sup>18</sup> Additionally, the use of the NRS score once a day, which is a self-assessment of intraoral pain,

enabled a more QOL-oriented analysis. As the regeneration cycle of oral mucosal epithelial cells is approximately 10 days, CIOM usually takes approximately 2 weeks to improve, even assuming that no secondary infection has occurred.<sup>19 20</sup> In this study, the ROAG scores of the mucous membrane domain and total scores were significantly improved in just 1 week. In addition, the patients showed complete resolution of their oral pain within a median period of 6 days, and all patients showed improvement in their post-treatment NRS scores. These results suggest that indigo naturalis ointment is a promising therapeutic agent for CIOM. Yoshimatsu *et al*<sup>21</sup> reported that a suppository of indigo naturalis is effective in treating patients with UC of the proctitis type. This suggests that indigo naturalis is absorbed locally through the mucosa. We hypothesised



**Figure 3** Revised oral assessment guide (ROAG) scores before and after treatment with indigo naturalis ointment. The total ROAG scores are shown on the left, and the ROAG scores of each of the eight domains are shown on the right. \*\* $P < 0.01$ .



**Figure 4** Changes in chemotherapy-induced oral mucositis due to the topical use of indigo naturalis ointment. Oral mucositis of the gum: (A) pretreatment (day 1); (B) after treatment (day 8); oral mucositis of the tongue: (C) pretreatment (day 1); (D) after treatment (day 10).

that the ingredients of indigo naturalis have a direct effect on oral mucositis; however, further research is needed to confirm this.

Although there is no established standard treatment, CIOM is generally treated with analgesics to reduce pain,<sup>22</sup> topical steroid ointments or non-steroidal anti-inflammatory drugs to reduce inflammation,<sup>23</sup> and sodium azulene sulfonate gargle to maintain oral cleanliness and moisture.<sup>24</sup> Steroid ointments, in particular, should be used with caution, as they can cause secondary infections. In the present study, the topical application of indigo naturalis ointment demonstrated prompt analgesic and mucosal healing effects with one therapeutic agent. Additionally, indigo naturalis ointment is considerably less expensive than other drugs, offering a medical economic advantage. The use of herbal medicines for CIOM is not considered unconventional, as their use has been reported with the administration of Hange-shasin-to.<sup>25</sup> The disadvantage of Hange-shasin-to is that it has a strong

bitter taste, whereas indigo naturalis ointment has the advantage of being tasteless and odourless. This may have contributed to its high feasibility.

Pulmonary arterial hypertension has been reported as an adverse event of indigo naturalis powder use in a patient with UC who orally ingested self-purchased indigo naturalis powder for 6 months.<sup>26</sup> However, a single dose of ointment for CIOM is approximately one finger-tip unit (FTU; less than 0.5 g), and even when ointment containing 20% indigo naturalis powder is used, the amount of indigo naturalis in one FTU is only 0.1 g or less. Although there is a difference between oral and topical use, the amount is approximately 1/20th of that used in the previous study on UC. In addition, the duration of use of the indigo naturalis ointment in this study was only 1 week, and therefore, the risk of serious adverse events caused by this treatment was considered very low.

This study has some limitations. First, this is a feasibility study and not a randomised, controlled trial with a placebo or a control group. Second, no histological studies were conducted. Third, it is unclear whether an ointment is the most appropriate dosage form or if gargles and sprays are more acceptable. Furthermore, the lack of data on long-term use of CIOM, despite the fact that it is a recurring condition, and the fact that the male to female ratio was skewed towards males and only two females were included in the study are additional limitations of this study. These issues should be considered in future studies.

## CONCLUSIONS

Overall, we found that treatment with indigo naturalis ointment is feasible and may be effective and safe for patients with CIOM. Indigo naturalis powder, which is highly effective in UC, was used to develop a treatment for CIOM, for which currently there is no standard treatment. Further large-scale clinical trials, such as randomised controlled trials, are expected in the future.

**Acknowledgements** We thank Naomi Yukawa for her expert technical assistance.

**Contributors** KH developed the feasibility study concept for CIOM and initiated the project with YY, YK, KT and TN assessed CIOM and provided expert advice on the study. Indigo naturalis ointment was developed by KH and dispensed by HM. A pilot study for IBD-induced oral mucositis was developed by KH and performed by KH, MN and TK. KH performed the statistical analysis. KH, YY, YH, SH and YS contributed to the trial design, its modifications and data collection. KH drafted the paper. KH is responsible for the overall content as guarantor. All authors have read and approved the final manuscript.

**Funding** The authors have not declared a specific grant for this research from any funding agency in the public, commercial or not-for-profit sectors.

**Competing interests** None declared.

**Patient consent for publication** Not applicable.

**Table 2** Changes in Numerical Rating Scale (NRS) for oral cavity pain after prescription of indigo naturalis ointment in patients with chemotherapy-induced oral mucositis

	NRS score		P value*
	Mean±SD	Median (IQR)	
Day 1 (prescription date)	4.74±1.76	5.00 (3.00–6.00)	–
Day 2	4.06±2.05	3.50 (2.00–5.00)	0.747
Day 3	3.37±2.60	2.00 (1.00–5.00)	0.264
Day 4	2.50±2.44	2.00 (0.00–5.00)	0.033
Day 5	1.76±2.16	1.00 (0.00–3.00)	0.001
Day 6	1.34±1.86	0.00 (0.00–2.50)	<0.001
Day 7	1.18±1.78	0.00 (0.00–2.00)	<0.001
Day 8	0.74±1.59	0.00 (0.00–1.00)	<0.001

\*Comparison with NRS score of day 1.

**Ethics approval** The study protocol was reviewed and approved by the Ethics Committee of Keio University School of Medicine (approval no. 20160289).

**Provenance and peer review** Not commissioned; externally peer reviewed.

**Data availability statement** Data are available on reasonable request. The datasets generated and/or analyzed during the current study are available from the corresponding author on reasonable request. ORCID iD Kenro Hirata <https://orcid.org/0000-0003-4536-7781>.

**Open access** This is an open access article distributed in accordance with the Creative Commons Attribution Non Commercial (CC BY-NC 4.0) license, which permits others to distribute, remix, adapt, build upon this work non-commercially, and license their derivative works on different terms, provided the original work is properly cited, appropriate credit is given, any changes made indicated, and the use is non-commercial. See: <http://creativecommons.org/licenses/by-nc/4.0/>.

#### ORCID iD

Kenro Hirata <http://orcid.org/0000-0003-4536-7781>

#### REFERENCES

- Cheng KK-F, Leung SF, Liang RHS, *et al*. Severe oral mucositis associated with cancer therapy: impact on oral functional status and quality of life. *Support Care Cancer* 2010;18:1477–85.
- Sonis ST, Oster G, Fuchs H, *et al*. Oral mucositis and the clinical and economic outcomes of hematopoietic stem-cell transplantation. *J Clin Oncol* 2001;19:2201–5.
- Vera-Llonch M, Oster G, Ford CM, *et al*. Oral mucositis and outcomes of allogeneic hematopoietic stem-cell transplantation in patients with hematologic malignancies. *Support Care Cancer* 2007;15:491–6.
- Naidu MUR, Ramana GV, Rani PU, *et al*. Chemotherapy-induced and/or radiation therapy-induced oral mucositis—complicating the treatment of cancer. *Neoplasia* 2004;6:423–31.
- Sonis ST. Pathobiology of oral mucositis: novel insights and opportunities. *J Support Oncol* 2007;5:3–11.
- Stasiak N, Kukuła-Koch W, Głowniak K. Modern industrial and pharmacological applications of indigo dye and its derivatives—a review. *Acta Pol Pharm* 2014;71:215–21.
- Zhou D, Chen W, Li X, *et al*. Evidence-based practice guideline of Chinese herbal medicine for psoriasis vulgaris (Bai Bi). *Eur J Integr Med* 2014;6:135–46.
- Yuan G, Ke Q, Su X, *et al*. Qing Dai, a traditional Chinese medicine for the treatment of chronic hemorrhagic radiation proctitis. *Chin Ger J Clin Oncol* 2009;8:114–6.
- Naganuma M, Sugimoto S, Mitsuyama K, *et al*. Efficacy of indigo naturalis in a multicenter randomized controlled trial of patients with ulcerative colitis. *Gastroenterology* 2018;154:935–47.
- Behnsen J, Raffatellu M. Keeping the peace: aryl hydrocarbon receptor signaling modulates the mucosal microbiota. *Immunity* 2013;39:206–7.
- Liu JZ, Pezeshki M, Raffatellu M. Th17 cytokines and host-pathogen interactions at the mucosa: dichotomies of help and harm. *Cytokine* 2009;48:156–60.
- Souwer Y, Szegedi K, Kapsenberg ML, *et al*. IL-17 and IL-22 in atopic allergic disease. *Curr Opin Immunol* 2010;22:821–6.
- Lin Y-K, Leu Y-L, Huang T-H, *et al*. Anti-inflammatory effects of the extract of indigo naturalis in human neutrophils. *J Ethnopharmacol* 2009;125:51–8.
- Lin Y-K, Wong W-R, Chang Y-C, *et al*. The efficacy and safety of topically applied indigo naturalis ointment in patients with plaque-type psoriasis. *Dermatology* 2007;214:155–61.
- Eilers J, Berger AM, Petersen MC. Development, testing, and application of the oral assessment guide. *Oncol Nurs Forum* 1988;15:325–30.
- Andersson P, Hallberg IR, Renvert S. Inter-rater reliability of an oral assessment guide for elderly patients residing in a rehabilitation ward. *Spec Care Dentist* 2002;22:181–6.
- Farrar JT, Young JP, LaMoreaux L, *et al*. Clinical importance of changes in chronic pain intensity measured on an 11-point numerical pain rating scale. *Pain* 2001;94:149–58.
- Wilkes JD. Prevention and treatment of oral mucositis following cancer chemotherapy. *Semin Oncol* 1998;25:538–51.
- Sonis ST. Mucositis as a biological process: a new hypothesis for the development of chemotherapy-induced stomatotoxicity. *Oral Oncol* 1998;34:39–43.
- Pico JL, Avila-Garavito A, Naccache P. Mucositis: its occurrence, consequences, and treatment in the oncology setting. *Oncologist* 1998;3:446–51.
- Yoshimatsu Y, Naganuma M, Sugimoto S, *et al*. Development of an indigo naturalis suppository for topical induction therapy in patients with ulcerative colitis. *Digestion* 2020;101:492–8.
- Lalla RV, Bowen J, Barasch A, *et al*. MASCC/ISOO clinical practice guidelines for the management of mucositis secondary to cancer therapy. *Cancer* 2014;120:1453–61.
- Lalla RV, Sonis ST, Peterson DE. Management of oral mucositis in patients who have cancer. *Dent Clin North Am* 2008;52:61–77. viii.
- Shida T, Kato T, Tomita Y, *et al*. Preventive effect of gargling with sodium azulene sulfonate on everolimus-induced stomatitis. *Palliat Care Res* 2014;9:122–7.
- Matsuda C, Munemoto Y, Mishima H, *et al*. Double-blind, placebo-controlled, randomized phase II study of TJ-14 (Hangeshashinto) for infusional fluorinated-pyrimidine-based colorectal cancer chemotherapy-induced oral mucositis. *Cancer Chemother Pharmacol* 2015;76:97–103.
- Nishio M, Hirooka K, Doi Y. Chinese herbal drug natural indigo may cause pulmonary artery hypertension. *Eur Heart J* 2016;37:37.